

FRACTORA: A NOVEL METHOD FOR DEEP RADIO-FREQUENCY FRACTIONAL RESURFACING AND TOTAL SKIN REJUVENATION

R. Stephen Mulholland, MD, FRCS(C), Michael Kreindel, Ph.D

Introduction

Carbon Dioxide laser skin resurfacing (LSR) gained great popularity in the 1990's because of impressive results seen with skin tightening, wrinkle reduction, improving skin texture and tone after a single treatment session. [1,2] One of the unique features of CO₂ laser resurfacing is that it creates almost equal ablation, coagulation and residual sub-necrotic 50-100 micron thermal zones in the skin. [3] The main disadvantages of the procedure were relatively long downtimes with surface discharge followed by prolonged erythema and then long-term risks of hypopigmentation resulting from a poor reservoir of epidermal cells and melanocytes after deep skin ablation.

One of the significant advances in laser skin rejuvenation was the introduction of ablative fractional skin resurfacing [4-6], where small areas of skin, with depths in the range of 100-800 microns were treated with in a fractional fashion, leaving a proportion of the skin intact around the ablative thermal column, keeping this undamaged skin around for fast skin healing after the fractional ablative laser treatment. Over several years and multiple different lasers and wavelengths, the majority of laser manufactures have focused on Fractional CO₂ resurfacing [7-8], either as a single aggressive treatment or in several more mild sessions, providing dramatic improvement in skin dyschromia, texture, wrinkles and acne scars, with relatively short downtime and a low rate of side effects that can be minimized by correct patient selection.

An alternative ablative technology is radio-frequency (RF) fractional skin resurfacing [8], which in published studies promotes more superficial ablation and is more focused on non-coagulative dermal residual heat. This relatively comfortable treatment demonstrates some level of improvement over a multiple treatment program. We believe that RF technology need not be limited by this superficial

ablative approach, but rather, it can be extended to CO₂ like ablative results for effective resurfacing combined with simultaneous non-coagulative deep dermal heating.

The current study demonstrates the results with a new fractional RF ablative rejuvenation technology providing a complete single treatment solution for aging patients.

Materials and Methods

15 patients with an age range of 34-65 years old and skin type I to V received a single full face, ablative fractional radiofrequency treatment using the Fractora hand piece of the BodyTite device (Invasix Ltd.). The Fractora hand-piece comes in an array of sharp RF conductive needles. Each needle is 600 microns long and 100 microns wide. There is a 60 Pin tip that provides 10% surface coverage and a 20 Pin tip for the upper and lower lid and lip lines for localized small lesions. The 20 Pin tip is a row of 20 bipolar Pins, while the 60 Pin tip has flat rail electrodes on either side of the needle array (see figure 1). The Fractora hand-piece is powered by the Bodytite platform and RF energy per pin, pulse sequencing and repetition rate is set on the device interface prior to treatment.

All patients were observed for a minimum of 4 months following the treatment. For pain control all patients underwent subcutaneous tumescent anesthesia with a mixture of 1 bottle of 1% lidocaine mixed in 1 liter of Ringers lactate and 2ml of epinephrine 1:1000. Approximately 150 cc of infiltrate was used on the forehead, cheek and lower face and another 100 cc if the neck was treated. Prior the tumescent anesthesia, Supra-orbital, Infra-orbital, Zygomatic-facial and –temporal, and mental nerve blocks were performed with 10cc of 1% xylocaine.

After waiting 8-10 minutes for the epinephrine effect, a full face, single pass, ablative fractional RF treatment was applied using the 60 Pin Fractora

Hand-piece. For those regions with deeper rhytides, such as the upper lips, lower lids or acne scars, a second pass was delivered. Lower lid, upper lid and deeper upper lip lines received a second pass with either the 60 Pin or 20 Pin tip.

Energy is applied to the skin through the matrix of sharp pins, each having length of 600 microns. Energy per pin was varied depending on skin type and thickness. For light and thick skin 50-62mJ/pin was applied, while for darker and thinner skin 30-40 mJ/pin were used. Figure 1 schematically shows RF current distribution between pins and side electrodes.

The Fractora Pins create a typical “CO2 and laser like” injury with a zone of vaporization (ablation), zone of coagulation and then zone of non-specific thermal stimulation. (Figure 1)

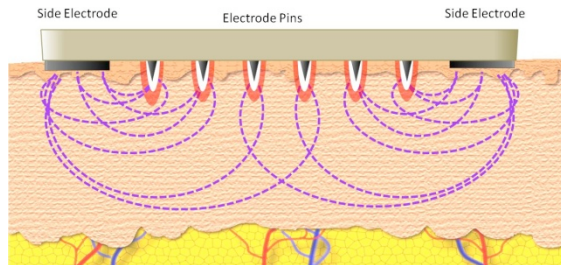


Figure 1 - Schematic distribution between pins and side electrodes.

With the Fractora electrode geometry, in addition to the typical ablative injury seen with CO2, Fractora Pins also act as bipolar electrodes and send radiofrequency energy from the tip of the ablative Pin and injury to the electrodes on two non-pin, flat electrodes on either side of the tip. This non-ablative, non-specific dermal matrix heating adds significant additional skin tightening, that one does not receive with traditional laser fractional ablative tissue injuries.

Antibiotic ointment was applied after the treatment. and the skin kept moist with Aquaphor for 3-4 days until camouflage make-up can be applied. Standard photographs were taken prior to the treatment and at the 6-month follow appointment Patients were advised to take a few days off following the treatment. Histology was taken immediately after treatment, 1 week and 3 weeks post treatment to analyze the characteristics of the ablative lesions and

the fractional wound healing process. Samples were stained with hematoxylin and eosin showed classic signs of fractional ablative coagulated tissue, phagocytosis and collagen remodeling.

Results and Discussion

Following the treatment and depending upon the parameters, intense edema and erythema were observed and lasted for up to 1 week, with a minor degree of edema being observed for up to 2 weeks. Small crusted dots, representing the ablated epidermal-dermal tissue at the opening of the ablative crater, appeared the next day following the treatment and were observed for several days to 1 week after the procedure before flaking off. Histological images shown in Figure 1 presents treatment results and healing process after the Fractora fractional ablative RF treatment with energy settings of 60mJ/pin. Histological study demonstrated a typical, strong, ablation effect as shown in figure 2a. The crater depth (zone of ablation) is on average 500-600 microns deep going through the epidermis, the papillary dermis and to the mid- and deep reticular dermis. The architecture and shape of the zone of ablation is a typical upside down pyramid (smaller at the base) also seen with CO2 lasers. One can also see the zone of coagulation measuring 60-100 microns in width surrounding the ablation crater (zone of ablation). (Figure 2a) Figure 2b shows phagocytosis in the healing crater (zone of ablation) at 1-week follow-up and the initiation of neo-collagenesis with new collagen fibers being formed. Figure 2c shows the treated zone structure 2 weeks after the treatment. The phagocytosis is almost completed and new collagen was formatted in the healed crater and the surrounding area of non-ablative heating.

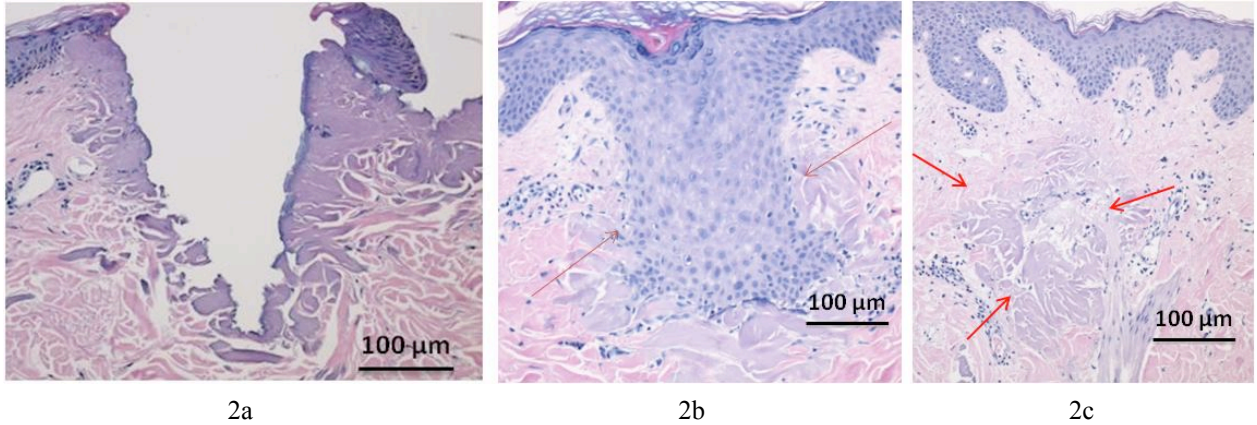


Figure 2 - Treatment zone immediately after the treatment (a), 1 week after the treatment (b) and 2 weeks following the procedure (c).

Figure 3 shows a female patient before and 6 months after a Full Face Fractora treatment, together with lower lid and orbital-malar volumization with a Hyaluronic add gel. The Fractora treatment was delivered at 60MJ/pin and the before and after photographs demonstrate skin tightening, lower lid and peri-oral wrinkle reduction, and an overall improvement of skin quality.

Figure 4 shows a skin type IV patient before and 6 months after a Full Face Fractora only treatment. The

energy delivery was 50mj/pin and the treatment demonstrated a significant reduction of pigmented lesions comparable with IPL treatment, reduction of peri-oral lines and significant improvement of skin quality.

Patients with rosacea and facial telangiectasia were treated effectively with the Fractora, which also acted as an RF coagulator in improving these facial vascular lesions. (Figure 5)

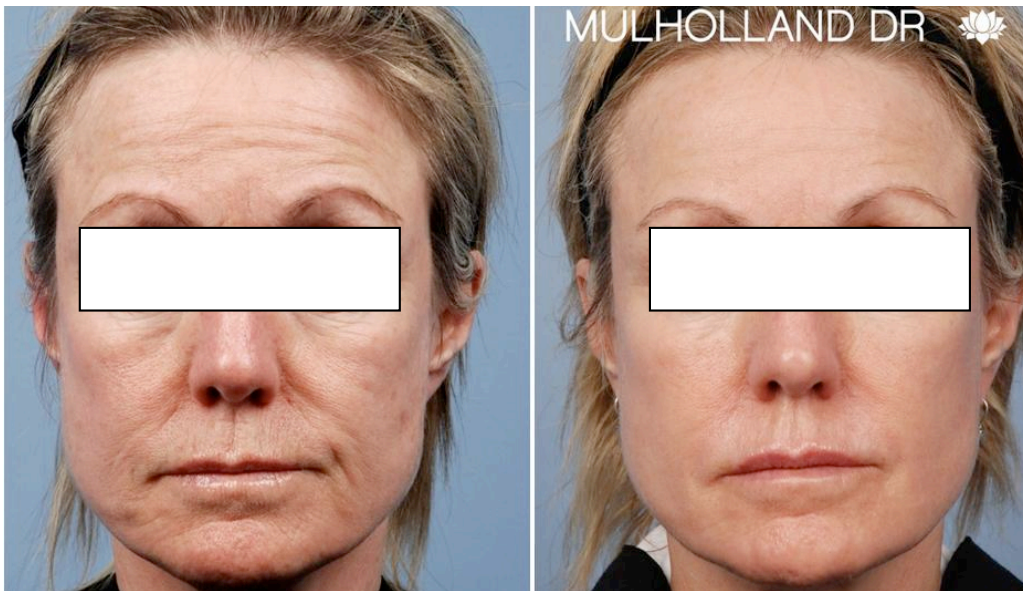

Figure 3 - Female patient before the treatment and 6 months after the single full face Fractora treatment

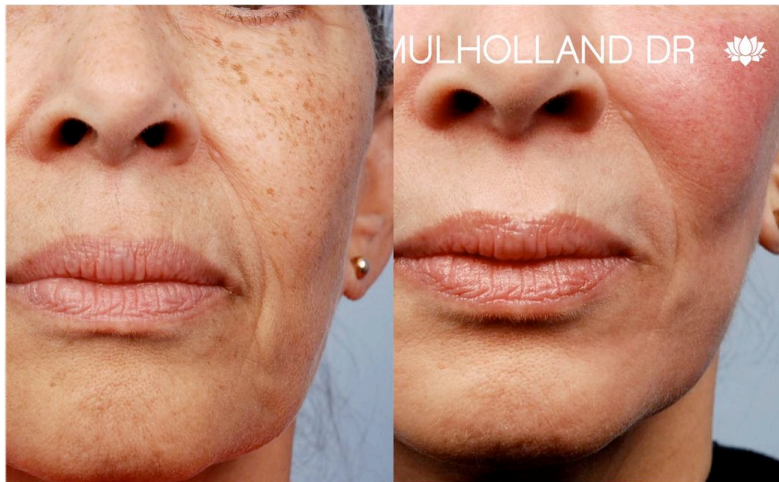

Figure 4 - Female patient before the treatment and 64 months after a single full face treatment

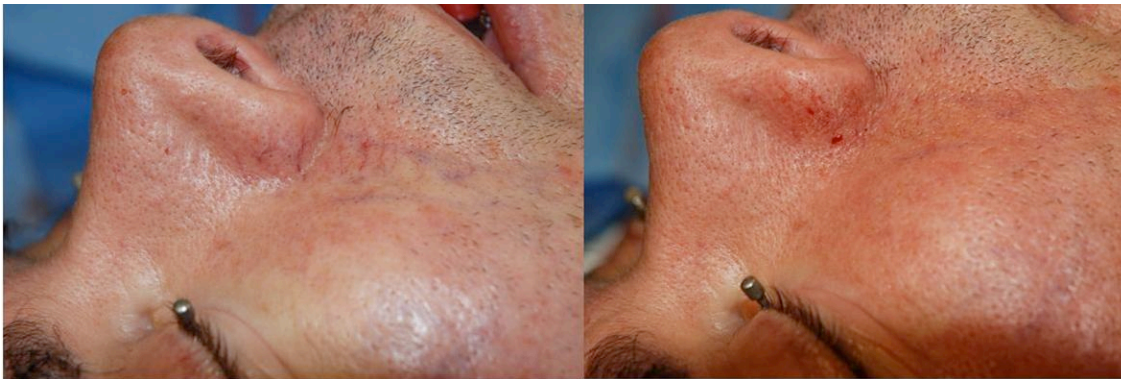

Figure 5 - Nasal spider vessels before and immediately after Fractora treatment

Conclusion

The histology confirms the Fractora fractional ablative RF lesion reproduces many of the same characteristic features those seen with Fractional CO₂ and ablative laser resurfacing. The Fractora has the additional benefit of a strong, bipolar RF non-ablative, non-coagulative dermal matrix stimulation not seen with ablative lasers.

Fractional Ablative Radiofrequency treatment with a deep needle based delivery system is a novel and unique fractional, ablative system in that acts as a Total Skin Rejuvenation system that can:

- induce wrinkle reduction and skin tightening;
- deliver additional non-ablative, bipolar RF dermal matrix thermal stimulation which provides

additional skin tightening over and above that seen with the ablation;

- improves melanin lesions and dyschromia;
- removes superficial vascular lesions.

Fractora is a novel skin rejuvenation fractional ablative system that combines the best of the Intense Pulsed Light, non-ablative skin tightening and fractional ablative resurfacing as it delivers reduction in hemoglobin and melanin based lesions, while significant improvement in wrinkles, texture and skin tightening .

All patients re-epithelialized within 4-7 days. There were no cases of delayed healing, no significant adverse reactions and specifically, no hypopigmentation, post inflammatory hyper-pigmentation (PIH) and no hypertrophic or hypotrophic scars.

References

1. Fitzpatrick RE, Tope WD, Goldman MP, Satur NM. Pulsed carbon dioxide laser, trichloroacetic acid, Baker-Gordon phenol, and dermabrasion: a comparative clinical and histologic study of cutaneous resurfacing in a porcine model. *Arch Dermatol.* 1996;132:469-471.
2. Alster TS, Kauvar AN, Geronemus RG. Histology of high-energy pulsed CO₂ laser resurfacing. *Semin Cutan Med Surg.* 1996;15:189-193.
3. Ross EV, McKinlay JR, Anderson RR. Why does carbon dioxide resurfacing work? A review. *Arch Dermatol.* 1999 Apr;135(4):444-54.
4. Bass LS. Rejuvenation of the aging face using Fraxel laser treatment. *Aesthet Surg J.* 2005 May-Jun;25(3):307-9
5. . Graber EM, Tanzi EL, Alster TS. Side effects and complications of fractional laser photothermolysis: experience with 961 treatments. *Dermatol Surg.* 2008 Mar;34(3):301-5; 305-7.
6. .Chan NP, Ho SG, Yeung CK, Shek SY, Chan HH. Fractional ablative carbon dioxide laser resurfacing for skin rejuvenation and acne scars in Asians. *Lasers Surg Med* 2010 Nov 42(9):615-23.
7. Hantash BM, Bedi VP, Kapadia B, Rahman Z, Jiang K, Tanner H, Chan KF, Zachary CB, In vivo histological evaluation of a novel ablative fractional resurfacing device. *Lasers Surg Med.* 2007 Feb;39(2):96-107.
8. Hruza G, Taub AF, Collier SL, Mulholland SR. Skin rejuvenation and wrinkle reduction using a fractional radiofrequency system. *J Drugs Dermatol.* 2009 Mar;8(3):259-65.